

Digital Imaging in Rhinoplasty

Xerxes Punthakee · Richard Rival ·
Philip Solomon

Received: 25 March 2008 / Accepted: 31 March 2009 / Published online: 13 May 2009
© Springer Science+Business Media, LLC and International Society of Aesthetic Plastic Surgery 2009

Abstract

Background Imaging in facial plastic surgery is becoming common. With the advances of digital imaging software, modifications of preoperative images for rhinoplasty patients can help to predict outcomes. The primary objective of this study was to determine whether preoperative digital image modification in rhinoplasty patients is useful in predicting postoperative outcomes.

Methods Patients undergoing rhinoplasty were prospectively collected and underwent preoperative digital imaging modifications using computer software. Postoperative images were compared to the preoperative modified images. Rankings for similarity were performed by patients and surgeons. Wilcoxon ranked-pairs test was used to compare the groups with a predetermined P value of 0.05,

and levels of agreement were assessed using weighted kappa scores.

Results One hundred twelve patients were collected and postoperative images were taken 11 months after surgery (range = 6–30 months). Frontal images were rated as poor, average, very close, or identical by patients 6.2, 52.7, 33.0, and 8.0%, and by surgeons 2.7, 61.6, 34.8, and 0.9%, respectively (Wilcoxon test, $P = 0.23$). Lateral images were rated as poor, average, very close, or identical by patients 1.8, 18.8, 48.2, and 31.3%, and by surgeons 0.9, 24.1, 59.8, and 15.2%, respectively (Wilcoxon test, $P = 0.0024$). Weighted kappa scores for agreement were 0.42 for frontal views of patients and surgeons and 0.65 for lateral views.

Conclusion Ratings by patients and surgeons comparing preoperative manipulated images with postoperative outcomes are predictive in approximately 75% of the patients, and lateral images are more useful for this goal. Level of agreement between patient and surgeon scoring is good for lateral images and moderate for frontal.

Presented at the International Congress of Facial Plastic Surgery, Cartagena, Colombia, 5–8 March 2008.

X. Punthakee

Department of Otolaryngology—Head and Neck Surgery,
University of Toronto, University Health Network—Toronto
General Hospital, 190 Elizabeth Street, RFE 3S-438, Toronto,
ON M5G 2N2, Canada
e-mail: xerxes.punthakee@utoronto.ca

R. Rival (✉)

Department of Otolaryngology—Head and Neck Surgery,
University of Toronto, 679 Davis Drive, #105, Newmarket,
ON L3Y5G8, Canada
e-mail: rrival3@rogers.com

P. Solomon

Department of Otolaryngology—Head and Neck Surgery,
University of Toronto, 57 Centre Street, Thornhill,
ON L4J1G2, Canada
e-mail: cpsolomon@rogers.com

Keywords Rhinoplasty · Digital imaging · Photography · Modification · Manipulation · Postoperative outcome · Comparison

Rhinoplasty is one of the most common procedures performed by facial plastic surgeons. For many years documentation of an individual's nose and the relationships of the face has been carried out using various techniques of imaging from silhouettes to photography and now, more recently, digital imaging. Imaging is recognized as a standard tool in the practice of facial plastic surgery and has major advantages to both the patient and the surgeon [1, 2].

Advances in computer technology and software have permitted the use of digital modification of preoperative imaging to help predict the outcome of a rhinoplasty [3, 4]. When used in a responsible, realistic fashion, the authors believe that computer imaging can be an educational experience for both the patient and the surgeon. The computer images are not a guarantee of a result but represent a common aesthetic goal to work toward. Despite the availability of this technology, many surgeons are reluctant to use it. They feel that it may give patients unrealistic expectations. The issue of medicolegal liability is often raised if the computer image results are not obtained [5, 6].

The reporting surgeons in this study have been using computer imaging for 5 years. The primary objective of this study was to determine whether preoperative digital image modification in rhinoplasty patients is useful in predicting postoperative outcomes. Secondary outcomes of interest included a comparison of the predictive values of frontal versus lateral views and levels of agreement between patients and surgeons.

Methods

Patients who were to undergo rhinoplasty were collected in a prospective manner from 2000 to 2006 by two surgeons (RR and PS). Preoperative photos were taken of all patients and included frontal, lateral, basal, and three-quarter views. Computer modification of the frontal and lateral images was performed using the Mirror Canfield Systems in consultation with the patient to help predict the outcome of the rhinoplasty. It was made clear that the images represented the goal of the surgery but there was no guarantee that the final outcome would match the images. The computer imaging was always performed by the operating surgeon.

Postoperative images were taken; during this same visit patients were shown the preoperative computer-manipulated images in addition to the postoperative images. All patients had undergone only one operation by the surgeon. Patients were asked to rank the frontal and lateral images on a scale of 1–4 (1 = poor match, 2 = average match, 3 = very close match, 4 = identical). The surgeons performed the same scoring for the other surgeons' patients. Informed consent was obtained preoperatively for all patients, including for the potential use of their images for research and their ratings of the images for research endeavors. Data were tabulated and statistical analysis of weighted kappa scores was performed using MedCalc statistical software (MedCalc Software, Mariakerke, Belgium). The Wilcoxon matched-pairs test was used as a nonparametric test that compares two paired groups, with a predetermined P value of 0.05.

Results

From 2000 to 2006, 112 patients (78 females, 34 males) who were to undergo rhinoplasty were prospectively collected to participate in this study from both surgeons' practices. The age range was 16–56 years (mean = 28.3 years). Postoperative imaging was performed between 6 months and 2.5 years after the rhinoplasty (mean = 11 months). Patient and surgeon comparisons of frontal and lateral preoperative computer-manipulated images can be seen in Figs. 1 and 2, respectively. Frontal images were rated as poor, average, very close, and identical by patients 6.2, 52.7, 33.0, and 8.0%, and by surgeons 2.7, 61.6, 34.8, and 0.9% respectively. A Wilcoxon matched-pairs test revealed a two-tailed probability of $P = 0.23$ for frontal view comparison. Lateral images were rated as poor, average, very close, and identical by patients 1.8, 18.8, 48.2, and 31.3%, and by surgeons 0.9, 24.1, 59.8, and 15.2%, respectively. A Wilcoxon matched-pairs test revealed a two-tailed probability of $P = 0.0024$ for lateral view comparison.

Overall, the patients' frontal and lateral images were considered very close or identical 41.1 and 79.5% of the time for patients and 35.7 and 75.0% for surgeons, respectively.

To test for levels of agreement, weighted kappa scores were calculated. The test of agreement shows a weighted kappa of 0.42 for frontal views of patients and surgeons, and 0.65 for lateral views. When testing for levels of agreement between patients' frontal and lateral views, weighted kappa was 0.49, and for surgeons kappa was 0.89. Strength of agreement for kappa scores from 0.41 to 0.60 is considered moderate, from 0.61 to 0.80 is considered good, and from 0.81 to 1.00 very good.

Discussion

The study population's demographics were similar to those of most rhinoplasty practices. The preponderance of

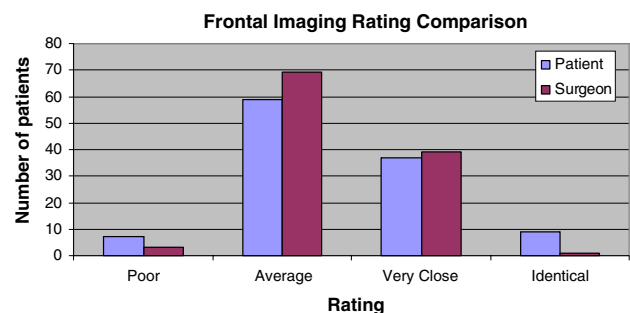


Fig. 1 Frontal imaging rating comparison between patient and surgeon

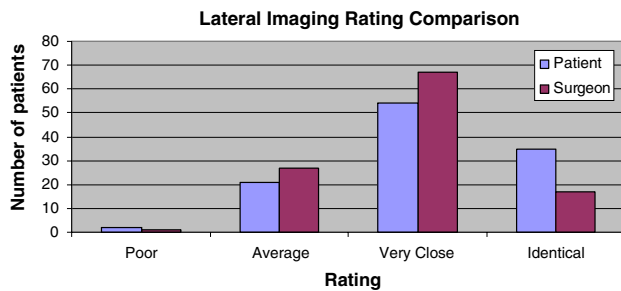


Fig. 2 Lateral imaging rating comparison between patient and surgeon

females and a mean age of 28.3 years is in keeping with traditional practices.

Imaging was performed a mean of 11 months after the rhinoplasty. The authors recognize that some may perceive the postoperative images at 6 months to be too early for assessing results; however, most swelling and dynamic postoperative changes have minimized by 6 months.

Surgeons did not score their own patients in order to decrease the amount of bias associated with the results since better scores would likely reflect a better perception of success. In general, frontal image comparisons were less likely to result in identical matches than were lateral images, which is illustrated in Figs. 1 and 2. The frontal image is more difficult to assess because of poor depth perception in facial images and more subtle relationships that are changed in the course of a rhinoplasty, such as alar base and tip width or columellar hang. Lateral imaging reveals more obvious and common rhinoplasty components that are modified during rhinoplasty, such as dorsal hump reduction and tip projection.

The Wilcoxon matched-pairs test for frontal images comparing patients' scores with surgeons' scores revealed a two-tailed probability of $P = 0.2301$, meaning that there is no reason to conclude that the overall median rankings differ. This is in contrast to the lateral images for which $P = 0.0024$. This significant difference can be explained by the concept that more useful, distinguishing information is visible on lateral images and thus differences in scores become more evident.

Overall, very close or identical scores were lower for frontal views by both patient and surgeon (41.1 and 35.7%) compared to lateral views (79% and 75%). These results are comparable to other rates described in the literature [3, 7]. In both cases, surgeons are more critical when comparing the images as revealed by lower percentages in both categories.

In terms of agreement between patient and surgeon, weighted kappa scores revealed a moderate strength of agreement for the frontal views (weighted kappa 0.422) and good strength of agreement for the lateral views

(weighted kappa 0.650). This illustrates that there is a better level of agreement for lateral views, which is important considering that the surgeon's judgment should coincide with the patient's judgment.

Fortunately, the authors did not incur any medicolegal action from the patients with respect to their computer imaging and final results.

We recognize that there are some limitations to the study. Postoperative images were taken as early as 6 months after surgery. This may be controversial in terms of revealing final outcomes; however, this would have the effect of underestimating agreement. Because there were two surgeons involved in the study, it is possible that overall scoring definitions of "very close" or "poor" may be different and could be reflected in outcome scores. This information is useful to those who currently pursue the practice of simulation images; however, it is not applicable to those surgeons who do not use this type of computer software. Ewart et al. [8] have gotten good results with the use of less expensive computer software than the traditional software currently being used by us and other facial plastic surgeons. This may encourage more surgeons to adopt this practice for the benefit of themselves and their patients.

Conclusion

Computer image modification in rhinoplasty has several advantages. Our study shows that ratings by patients and surgeons comparing preoperative modified images with postoperative outcomes is predictive in approximately 75% of patients and that lateral images are more useful for this goal. We also show that the level of agreement between patient and surgeon scoring is good for lateral images and moderate for frontal images. Digital image modification is an excellent tool for which the advantages outweigh the disadvantages and it can have a positive impact on a rhinoplasty practice.

References

1. Galdino GM, DaSilva D, Gunter JP (2002) Digital photography for rhinoplasty. *Plast Reconstr Surg* 109(4):1421–1434
2. Bronz G (1999) The role of the computer imaging system in modern aesthetic plastic surgery. *Aesthetic Plast Surg* 23(3):159–163
3. Vuyk HD, Stroomer J, Vinayak B (1998) The role of computer imaging in facial plastic surgery consultation: a clinical study. *Clin Otolaryngol Allied Sci* 23(3):235–243
4. Sharp HR, Tingay RS, Coman S, Mills V, Roberts DN (2002) Computer imaging and patient satisfaction in rhinoplasty surgery. *J Laryngol Otol* 116(12):1009–1013

5. Chavez AE, Dagum P, Koch RJ, Newman JP (1997) Legal issues of computer imaging in plastic surgery: a primer. *Plast Reconstr Surg* 100(6):1601–1608
6. Parodi PC, Moreschi C, Rampino E, Codarini M, De Biasio F, Riberti C (2003) Corrective rhinoplasty: medical and legal aspects. *Acta Otorhinolaryngol Ital* 23(5):356–361
7. Muhlbauer W, Holm C (2005) Computer imaging and surgical reality in aesthetic rhinoplasty. *Plast Reconstr Surg* 115(7):2098–2104
8. Ewart CJ, Leonard CJ, Harper JG, Yu J (2006) A simple and inexpensive method of preoperative computer imaging for rhinoplasty. *Ann Plast Surg* 56(1):46–49